

See discussions, stats, and author profiles for this publication at: <https://www.researchgate.net/publication/340774085>

# Anatomical software as a tool in the teaching–learning process of human anatomy. Literature Review

Article in *The FASEB Journal* · April 2020

DOI: 10.1096/fasebj.2020.34.s1.09262

CITATIONS

3

READS

107

6 authors, including:



**Andrés Santana**

Universidad de las Américas (Chile)

6 PUBLICATIONS 7 CITATIONS

SEE PROFILE



**Paulo Andres Orquera**

Anáhuac University

7 PUBLICATIONS 8 CITATIONS

SEE PROFILE



**Juan Valenzuela**

Unab

48 PUBLICATIONS 60 CITATIONS

SEE PROFILE



**Mathias Orellana**

Universidad Andrés Bello

31 PUBLICATIONS 31 CITATIONS

SEE PROFILE

# Anatomy of the lateral pterygoid muscle and its relationship with temporomandibular disorders. A literature review

Juan José Valenzuela<sup>1,3</sup>, Mathias Orellana<sup>2</sup>, Marjorie Gold<sup>1</sup>, Guernica Garcia<sup>1</sup>, Andrés Santana<sup>3</sup>

<sup>1</sup>University Andrés Bello. Department of Morphology, Faculty of Medicine, Av. Republic 259, Santiago, Chile

<sup>2</sup>Department of Morphological Sciences, Faculty of Medicine and Science, University San Sebastian, Santiago, Chile

<sup>3</sup>Department of Morphology and Function, Faculty of Health, University of the Americas, Chile

## SUMMARY

The lateral pterygoid muscle is a chewing muscle that is found bilaterally in the cranial region. Anatomically, the lateral pterygoid muscle is made up of two bellies, an upper belly and a lower belly. Its anatomical description present in the scientific literature showed that there is an anatomical difference or variation, mainly the insertions of the upper belly of the lateral pterygoid muscle at the level of the temporomandibular joint, and specifically in the disc and articular condyle, although distributions are reported similarly. They are not entirely accurate in smaller quantities: some articles reported variations in the insertion of the lower belly and others the appearance of a third belly of the lateral pterygoid muscle or medial belly. As mentioned above, a high number of studies that presented some type of lateral pterygoid muscle variation was associated with some type of temporomandibular disorders of the joint or some of its intra or extra-articular components. A review of the literature in scientific databases was carried out after the selection of the scientific articles, which were analyzed in full text, and the relationship between the anatomy of the lateral pterygoid muscle

and the temporomandibular disorders was sought.

**Key words:** Anatomical sciences – Lateral pterygoid muscle – Temporomandibular joint – Temporomandibular dysfunction – Human body

## INTRODUCTION

### *Anatomy of the lateral pterygoid muscle*

The lateral Pterygoid Muscle (LPM) is a key component of the stomatognathic system that plays an important role during the chewing cycle, in spite of its small size (Hauddodi et al., 2005). The LPM participates directly in the movements of the temporomandibular joint (TMJ), actively collaborating in the chewing process. This muscle has a triangular shape quite symmetrical in all its margins (Usui et al., 2008). Numerous studies have been carried out to see the functional characteristics of the LPM and its relationship with the TMJ dysfunction. Anatomically, the classical literature describes two bellies of the LPM, an upper belly and a lower belly (Moore et al., 2013). The lower belly has its proximal insertion on the outer surface of the lamina of the lateral pterygoid process, while the upper belly has its proximal insertion on the lower surface of the major wing of the sphenoid bone and on the posterolateral surface of the sphenoid tubercle (Foucart et al., 1998). Both bellies run laterally and posteriorly to the TMJ, presenting their distal inser-

**Corresponding author:** PT Juan José Valenzuela. E-mail:

j.valenzuelafuenzali@uandresbello.edu

PT Mathias Orellana Donoso

E-mail: miorellanad@docente.uss.cl

Submitted: 28 October, 2019. Accepted: 21 March, 2020.

tion of the upper belly at the anteromedial edge of the mandibular condyle and the articular capsule of the same. In addition, a small group of muscle fibers of the upper belly join with the fibers of the lower belly for both groups of fibers inserted into the pterygoid fovea, while the lower belly has its distal insertion in the pterygoid fovea and in the neck of the mandible bone.

The motor innervation of the LPM comes from the anterior trunk of the mandibular nerve, which through three branches penetrates the two heads of the LPM. The upper head is innervated by the upper branch, while the lower head is penetrated by the lower and middle branch of the anterior trunk of the mandibular nerve. In the presence of the third head of the LPM, the division of the anterior trunk of the mandibular nerve and its three branches will be underlying each of the LPM heads, supplying them with the motor innervation (Foucart et al., 1998). The specific function of the LPM on the TMJ is to be the main agonist in the TMJ opening movement (Gómez de Ferrari et al, 2004). During the closing movement the upper belly of the LPM participates as a synergist to the movement (Usui et al., 2008; Osawa and Grossman, 2010), while the lower belly of the LPM participates as a synergist for the protrusion movement. Finally, in the laterality movement of the TMJ all the homolateral masticatory muscles participate in the direction of laterality movement (Usui et al., 2008). Associated with the movements, it is important to mention that 80% of the fibers that form the LPM are slow fibers (type I). This seems to indicate that these muscles are relatively resistant to fatigue and can serve to hold the condyle for prolonged periods without difficulty (Usui et al., 2008; Osawa and Grossman, 2010).

### **Anatomic variations of the lateral pterygoid muscle**

At present, several terms are used to refer to the morphological variations of the human anatomy, characteristics or non-metric features that can be located in any tissue, although it is the musculo-skeletal tissues, such as muscles and bones that have the greatest amount of anatomical variations. The features, which are characterized by the absence of fusion, are not considered anatomical variants until the normal developmental age that follows the age pattern has ended (Saunders and Rainey, 2007). Within an important number of anatomical variations that occur in the human body we will analyze the LPM, which as an anatomical variation describes the third muscular belly, accessory belly or middle belly.

### **Temporomandibular joint and its disorders**

The TMJ is a bilateral condylar synovial joint which allows the rotation of the mandibular condyle over the mandibular fossa of the temporal bone, allowing movements of opening, protrusion,

closure, retrusion and laterality of the mandible (Latarjet and Ruiz 2005). International anatomical terminology has unified a list of terms lacking in eponyms, with the aim of establishing a unified language in the scientific community. However, there are anatomical structures related to TMJ that are not mentioned by international anatomical terminology, such as the discomaleolar ligament of the TMJ (Fuentes et al., 2014).

Temporomandibular Disorders (TMD) correspond to a group of clinical conditions of different characteristics, mainly associated with the components of the stomatognathic system at the muscular and articular level. The experts in the field have looked for ways to unify the diagnostic criteria in order to generate a common language. For this reason, the International Network for Orofacial Pain and the Methodology of Related Disorders (INFORM) publishes the "Research for Diagnostic Criteria in Temporomandibular Disorders" (RDC/TMD) (Dworkin and Leresche, 1992), which is responsible for grouping TMD pathologies for rather research purposes.

In 2014, the INFORM published the new and revised diagnostic criteria for clinical and research purposes called "Diagnostic criteria in temporomandibular disorders" (DC / TMD) (Schiffman et al., 2014). In this update, clear instruments are published and standardized to perform an accurate clinical examination and present algorithms to arrive at a diagnostic hypothesis.

In the DC/TMD, the pathologies are grouped into discs, muscular and degenerative among others. The evaluation of the LPM is declared as a muscular condition and does not consider it within the causes of disc diseases, despite its anatomical relationship at the level of the distal insertion of the muscle.

In spite of the description mentioned, this review included articles that used terms of temporomandibular dysfunction, temporomandibular disorders, and orofacial pain among others.

Therefore, the purpose of this study was to review the literature regarding the morphology of the lateral pterygoid muscle (LPM) and its variants, and its correlation with temporomandibular disorders (TMD).

## **MATERIALS AND METHODS**

This review of the literature considered specific scientific articles and books of human anatomy written in Spanish or English, published between 2000 and 2019.

A systematic search was carried out in electronic databases in order to compile the available literature on the subject to be treated, taking as reference the PRISMA statement for revisions (Hutton et al., 2016). The search process was carried out in the following databases: MEDLINE, SCIELO, SPORT DISCUS, CINHAI, SCOPUS and

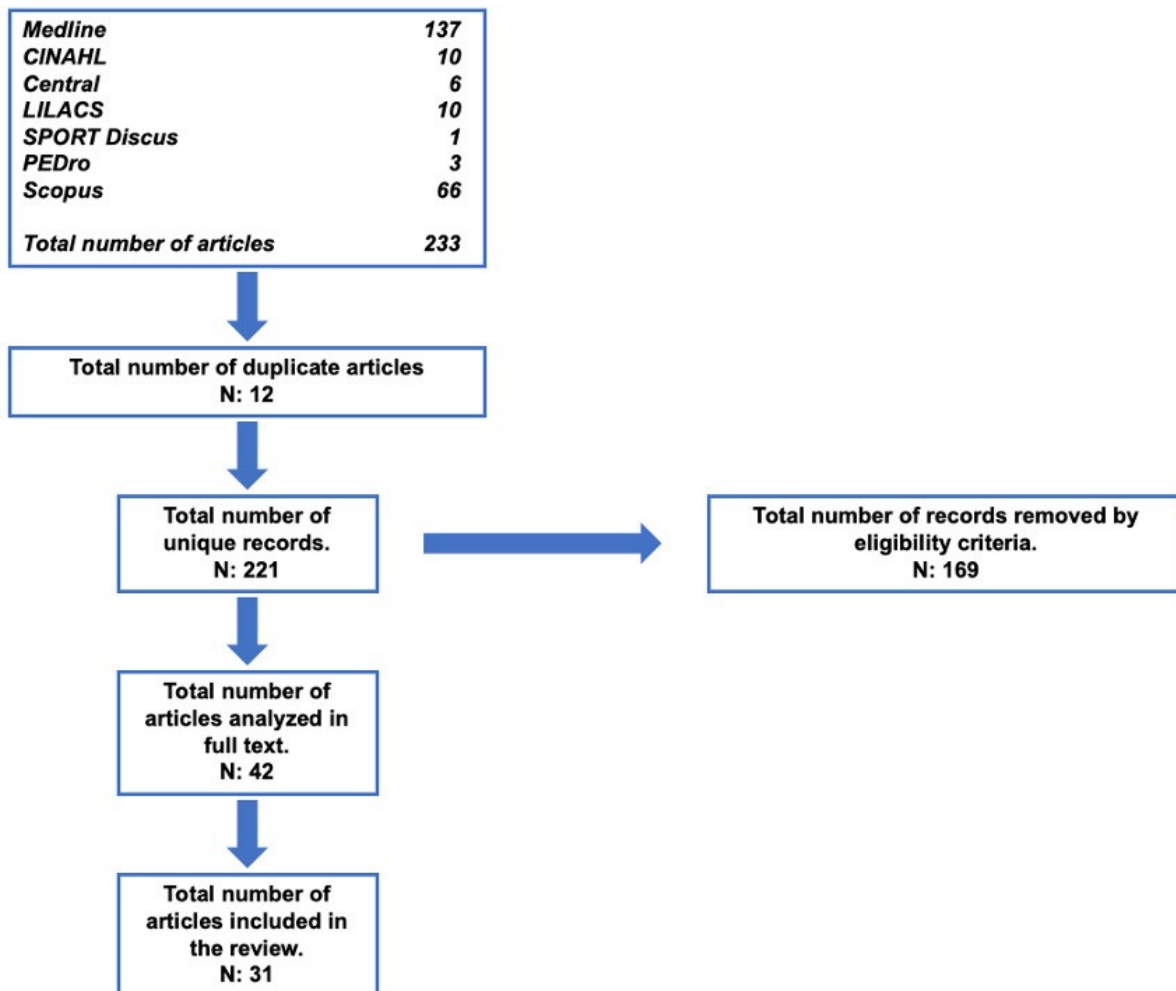
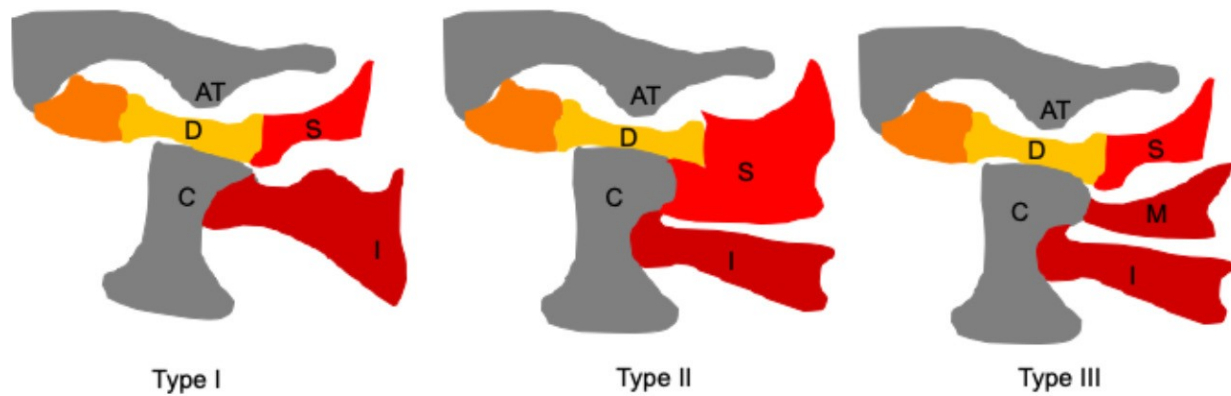


Fig 1. Search algorithm.

GOOGLE SCHOLAR until October 30, 2019 using as search terms "Muscle pterygoid lateral", "anatomy sciences", "anatomical variations", "temporomandibular joint" and "temporomandibular dysfunction", for which the following Boolean connectors "AND" "OR" and "NOT" were used. The search algorithm is shown in Fig. 1. The exclusion criteria were letters to the editor, bibliographic reviews and articles of gray literature.

In a first part, two researchers read the titles and summaries of the articles submitted for the search of the topic in order to define the line of research and the relevance of the topic; a third researcher reviewed the articles filtered by the first two authors mentioned above, giving a total of 33 articles that were reviewed in full text, verifying that they met the inclusion criteria established above. Upon completion of the reading and analysis, a total of 26 articles were included in this literature review: these scientific articles were published in English or Spanish between 2002 and 2019. In the review of the articles it was found that 11 of them made the comparison between anatomical variations of the LPM with the pathology of the temporomandibular joint or with TMD; 15 of the articles only de-

scribed the participation of the LPM in the TMD, but they did not show any kind of relationship in the changes in the morphology of the LPM and the TMD. Regarding the pathology, the term TMD in the articles left a gap in the terminology and definition of TMD since it was reported of various types of classifiers that defined the conditions of TMJ. However, the term that was mostly associated with TMD was the dysfunction of TMJ without specifying within the article the biomechanical, physiological or physiopathological behavior of the said condition. A high percentage of the studies included in this review (88%) directly correlated the dysfunction of the LPM with TMD. However, the term that was mostly described is the alterations of the temporomandibular joint, since it does not specifically describe which is the alteration presented the patients. Data extraction was performed by one researcher. The classic description described in books of the morphology of the LPM was recorded, as well as the anatomical variations of the LPM and the incidence of both in the TMD. The information collected was entered into a previously defined and designed table, where the data were analyzed and interpreted by all authors on a cloud mode platform, specifically on Google drive. The



**Fig 2.** Adapted figure of Dergin et al. (2012), in which it's shown the three types of attachments to the disc-condyle complex and the third belly of the LPM. (AT: articular tubercle, C: condyle, D: disc, S: superior lateral pterygoid muscles, I: inferior lateral pterygoid muscles, M: middle part of the lateral pterygoid).

anatomical description of the LPM and the bone and joint components of the TMJ was classified according to international anatomical terminology (IAT).

## RESULTS

### **Anatomic variations of the superior belly of the LPM**

The studies that reported the variation in the insertion at the TMJ level of the LPM. The muscle analyzes were performed through two magnetic resonance techniques or through dissection of corpses. The total number of patients who underwent the analysis through MRI was 698 patients among all studies, while 71 bodies were analyzed: of all of them it was reported that the fixation was performed through the formalin fixation technique and the dissection process was specific for masticatory muscles, TMJ or directly to identify the LPM and its bellies (Antonopoulou et al., 2013; Dergin et al., 2012; Imanimoghaddam et al., 2013; Mazza et al., 2009). Three types of LPM insertion were described: the first type of insertion identified that the muscle fibers were inserted in the articular disc and in the head of the mandible condyle; the second type of insertion was only in the mandible condyle; and the third type of insertion was in the joint space between disc and joint capsule, which is shown in Table 1 and Fig. 2 (Antonopoulou et al., 2013; Dergin et al., 2012; Imanimoghaddam et al., 2013; Mazza et al., 2009). Litko et al. (2016) in

their study of the morphology of the LPM, in which they evaluated 382 patients with magnetic resonance imaging, reported that the type of LPM insertion that was most prevalent was type II with 67%, while the one with the lowest prevalence was type I with a 7.6%. They also evidenced that the movement of the mandible and its morphometry directly interfered in the position of the TMJ, which also secondarily influences the insertion of the LPM (Litko et al., 2016). Finally, one of the anatomical variations less seen and described in the scientific literature is the one that Matsunaga et al. studied, where in 20 corpses they found LPM that presented its insertion in the articular disc but projected 4 types of fibers, which they described as: I) centromedial fibers that directed towards the insertion of the temporal muscle, II) the discotemporal fibers that projected towards the articular disc and towards the temporal muscle, III) the zygomatic-mandibular beam that projected towards the mandibular condyle and towards the zygomatic process of the temporal bone, lateral to the infratemporal fossa, and finally, IV) some fibers that were projected towards the back and inner part of the masseter muscle (Matsunaga et al., 2009). The most classic variations were the three types of LPM insertion, while the LPM fibers with disposition towards neighboring structures were only reported in one study and the same presented a sample that is not representative for the population.

### **Anatomic variations of the inferior belly**

The lower belly of the LPM is inferior to the upper belly, its morphology describes that the belly is present in the 97.7% of the western population. In the cases that both lower and upper belly have not been found, it has been described as a mass of common fibers that have no division and is classified only as lateral pterygoid muscle without specifying any of its 2 bellies (Melke et al., 2016). Regarding the described variations of the lower belly of the LPM, only the insertion at the base of the

**Table 1.** Types of muscle insertion of the LPM bellies

Insertion Type	Belly	Insertion
Type I	Superior	Disc
	Inferior	Condyle
Type II	Superior	Disc and condyle
	Inferior	
Type III	Superior	Disc
	Middle	Condyle
	Inferior	Condyle

mandible condyle is reported, which occurred as long as there was some variation in the insertion of the upper belly of the LPM. No study showed that some type of exclusive anatomical variation of the lower belly of the LPM.

### **Third belly of the LPM**

The LPM from the international anatomical theory is a masticatory muscle within the dental and anatomical specialties. It is considered as the main component of mastication either functionally or structurally by its direct insertion into the joint components of the TMJ. The LPM in some pathology of TMJ or TMD participates directly in these pathologies, directly or indirectly. If directly, it is described as the muscle that caused the pathology where it is mainly defined in the literature as temporomandibular dysfunction. This dysfunction alters the movement of the joint and causes pain in the area and in surrounding structures, whether nervous, vascular, or bone, pathologically defined when LPM is the cause of TMD or temporomandibular dysfunction (Imanimoghaddam et al., 2013; Mazza et al., 2009; Melke et al., 2016; Bernal et al., 2016; Bhutada et al., 2008; Coskun et al., 2009; Davies et al., 2012; D'ippolito et al., 2010; Ngamsom et al., 2017; Park et al., 2013). It is pathologically described that there is an impingement of the intra-articular components, but the mainly compromised anatomical structure is the articular disc, due to the association that it has with the LPM insertion in this articular structure. Mechanically this articular dysfunction produces an anterior displacement of the disc, which compresses it with bone structures, causing a bony stop with the mandibular condyle, reducing joint space and decreasing the range of joint movement, producing clinical and mechanical symptoms combined in most pathological cases (Antonopoulou et al., 2013). Other pathologies are associated with TMJ where the involvement of LPM is indirectly associated in pathologies such as chronic myofascial pain, pain of resting TMJ and oromandibular dystonia (Cao et al., 2012; Conti et al., 2008; Iwasaki et al., 2016). The pathologies mentioned above are not produced directly by the LPM. However, if this muscle is affected later in the pathology, and, even more, if the pathology becomes chronic either by neuromechanical components or by time components in what that the chronicity of a pathology is defined, mechanically the LPM in these pathologies with a secondary participation has the same behavior as when it is the primary factor. In some cases a muscular spasm occurs, which increases the continuous load at its insertion points mainly in the articular disc of the TMJ producing an articular impingement, so the symptoms increase, and if the LPM is not considered in the treatment, this pathological condition will not have a resolution to the causes

that are often overlooked by a conservative management of symptoms which can continue to damage structural components and promote the chronicity of the pathology (Yotsuya et al., 2009).

### **Correlation between the anatomic variations of the LPM and TMD**

The correlation between the types of LPM insertion and its anatomical variations with TMD is directly evidenced: it was especially stated in studies with temporomandibular dysfunction. Only the Dergin and Matsunaga studies (Dergin et al., 2012; Matsunaga et al., 2009) did not present a correlation between the variation of the LPM and the TMD. The above is attributed to the fact that these studies carried out a cadaveric anatomical study where only morphological characteristics of the LPM and its variations were seen. Due to this, no clinical nor pathological correlation was made. Among the studies analyzed, 81.1% of the studies characterized the participation of the LPM with some type of anatomical variation in its insertion or an additional belly. In the anatomical variations the insertion characterized as type II according to the Litko classification was the one that presented the greatest relationship with TMD specifically established by the insertion of the upper belly into the articular disc and mandibular condyle. Consistent with the above, it has a direct relationship with the insertion points that the type II insertion variation presents. This variation can produce temporomandibular alterations or dysfunction, which produces a mechanical alteration in the joint positioning, which leads to clinical alterations mainly expressed as joint pain or in surrounding areas, mainly during elevation and mandibular descent (Omami and Lurie, 2012). About the anatomical variation of the lower belly of the LPM, no study showed that there was some kind of relationship between the insertion of the lower belly of the LPM with some type of TMD, either primary or secondary. Regarding the middle belly or accessory belly of the LPM, which occurred in 19% of the studies analyzed, none reported a relationship between this variation of the LPM with some type of TMD, either primary or secondary, in acute or chronic pathologies of the TMJ (Kawakami et al., 2012; Gonzalez et al., 2015; Pereira et al., 2015; Manish et al., 2008). Table 2 includes the articles that presented or described an anatomical variation of the LPM and the relationship with the TMD.

## **DISCUSSION**

This review arises from the interest of knowing the morphological characteristics of the LPM and its relationship with TMD. This clinical anatomical review study, unlike that carried out by Desmons, which only analyzed the relationships that LPM presented with the temporomandibular disorders (Desmons et al., 2007), seeks to establish a rela-

**Table 2.** Correlation between the anatomical variation of the LPM and the TMD

Bibliographic reference	Anatomic Variation of the LPM	TMJ Disorder
Antonopoulou et al. (2013)	3 insertions in the joint disc.	Dysfunction in the anterior displacement of the articular disc.
Coskun et al. (2009)	3 heads of the lateral pterygoid muscle.	Temporomandibular dysfunction
Dergin et al. (2012)	Provision in patterns of variation in the insertion of the MPL, either in the articular disc and in the condyle.	No correlation was presented.
Desmons et al. (2007)	Provision in patterns of variation in the insertion of the LPM, either in the articular disc and in the condyle.	Temporomandibular dysfunction
Imanimoghaddam et al. (2013)	Provision in patterns of variation in the insertion of the LPM, either in the articular disc and in the condyle	Temporomandibular dysfunction
Kawakami et al. (2012)	Variation in the insertion of the lower head of the LPM.	Temporomandibular disorder.
Litko et al. (2016)	Variation in the insertion of the lower and upper head of the LPM, plus third head of the LPM.	Indirect correlation between insertion and joint disc abnormalities.
Matsunaga et al. (2009)	Variation in the insertion of the lower head of the LPM.	No correlation was presented.
Mazza et al. (2009)	Variation in the insertion of the upper and lower head of the LPM.	Temporomandibular dysfunction, dislocation of the joint disc.
Omami et al. (2012)	Variation in the insertion of the upper head of the LPM.	Symptomatic TMJ only with the presence of pain evaluated with VAS.
Melke et al. (2016)	Variation in the insertion of the upper head of the LPM.	Temporomandibular dysfunction.

tionship from different factors where the LPM could interfere in the proper functioning of the LPM and its characterization with the TMD. We also believe that our review is a contribution to treat the TMD considering different factors from the point of view of neighboring structures, whether muscular, articular, nervous or vascular. It is also essential to be considered as a clinical decision tool in the evaluation and treatment of patients with TMD, the characteristics of the LPM and its possible anatomical variations, or in the insertion site, since, as the studies have shown, a very high percentage of them correlated the TMD with the LPM. This review also leaves the window open to new studies that directly specify with participation of specific pathologies in the pathomechanics or clinic presentation of patients who are affected with it. This review favors the study for undergraduate, postgraduate and clinical students, mainly of dental and medical careers and people or patients who want to know their pathology better and ask for an informed clinical decision. Nevertheless, these data suggest the LPM has a role in the TMD none of the studies presented and found in this review took into account the importance of psychological factors that may contribute to the clinical presentation of the TMD. Staniszewski et al. (2009) made a clinical cross sectional study, where they aimed to assess the stress levels in TMD patients based on an upregulated HPA axis and compare the results with healthy individuals, and to analyze the saliva for F (cortisol) and E (cortisone) and the scores for self-reported anxiety/depression and catastrophizing from a questionnaire and they hypothesized that the TMD patients have an upregulated HPA axis shown by in-

creased psychological scores and increased level of cortisol in saliva. The results found that F and E levels in saliva are significantly higher in TMD patients compared to healthy individuals. This finding may indicate that TMD patients have an upregulated HPA axis (Staniszewski et al., 2018). This stress levels accompanied with emotional distress is also related to central sensitization especially with patients with chronic pain (Lorduy et al., 2013), but its presence on TMD patients is not clear and in relation to this, La Touche et al. (2018) conducted a systematic review regarding the presence of central sensitization in patients with TMD, where they support the existence of differences in widespread pressure pain sensitivity in patients with TMD when compared with asymptomatic subjects, and that spinal and central hyperexcitability can be found in TMD patients as shown by an increase in mechanical temporal summation which is related in turn to central sensitization. Taken these together, we suggest that the readers take our results and use them as a complement within their clinical reasoning process without leaving other factors into account when assessing and treating patients with TMD.

### Conclusion

The LPM is a muscle that plays an important role in the development of TMD. Within its variations in the number of bellies and insertions, the upper belly presents variations in its insertion in the TMJ, with Type III insertion being the most prone to develop TMD related symptoms due to early traction of the disc during mandibular descent. Although other factors need to be considered regarding the clinical picture, we believe that an adequate under-

standing of the upper belly morphology of LPM is crucial for the diagnosis and treatment of TMD.

## REFERENCES

- ANTONOPOULOU M, IATROU LA I, PARASCHOS A, ANAGNOSTOPOULOU S (2013) Variations of the attachment of the superior head of human lateral pterygoid muscle. *J Craniomaxillofac Surg*, 41(6): 91-97.
- BERNAL C, GONZALEZ O, MORENO M (2016) New anatomico-radiological findings of the lateral pterygoid muscle. *Surg Radiol Anat*, 54: 1-11.
- BHUTADA MK, PHANACHET I, WHITTLE T, PECK CC, MURRAY GM (2008) Regional properties of the superior head of human lateral pterygoid muscle. *Eur J Oral Sci*, 116(6): 518-524.
- CAO Y, ZHANG W, YAP AU, XIE QF, FU KY (2012) Clinical characteristics of lateral pterygoid myospasm: a retrospective study of 18 patients. *Oral Surg Oral Med Oral Pathol Oral Radiol*, 113(6): 762-765.
- CONTI PC, DOS SANTOS SILVA R, ROSSETTI LM, DE OLIVEIRA FERREIRA DA SILVA R, DO VALLE AL, GELMINI M (2008) Palpation of the lateral pterygoid area in the myofascial pain diagnosis. *Oral Surg Oral Med Oral Pathol Oral Radiol Endod*, 105(3): 61-66.
- COSKUN G, GOVSA F, OZGUR Z (2009) Examination of the heads of the lateral pterygoid muscle on the temporomandibular joint. *J Craniofac Surg*, 20: 219-223.
- DAVIES J, CHARLES M, CANTELM I B (2012) Lateral pterygoid muscle a three-dimensional analysis of neuromuscular partitioning. *Clin Anat*, 25: 576-583.
- DERGIN G, KILIC C, GOZNELI R (2012) Evaluating the correlation between the lateral pterygoid muscle attachment type and internal derangement of the temporomandibular joint with an emphasis on MR imaging findings. *J Cran Max Fac Surg*, 40: 459-463.
- DESMONS S, GRAUX F, ATASSI M, LIBERSA P, DUPAS PH (2007) The lateral pterygoid muscle, a heterogeneous unit implicated in temporomandibular disorder: a literature review. *J Cranio*, 25(4): 283-291.
- D'IPPOLITO SM, BORRI WOLOSKE AM, D'IPPOLITO G, HERBERT DE SOUZA B, FENYO-PEREIRA M (2010) Evaluation of the lateral pterygoid muscle using magnetic resonance imaging. *Dentomaxillofac Radiol*, 39(8): 494-500.
- DWORKIN SF, LERESCHE L (1992) Research diagnostic criteria for temporomandibular disorders: review, criteria, examinations and specifications, critique. *J Craniomandib Disord Fall*, 6(4): 301-355.
- FOUCART JM, GIRIN JP, CARPENTIER P (1998) Innervation of the human lateral pterygoid muscle. *Surg Radiol Anat*, 20(3): 185-189.
- FUENTES R, BUCCHI C, CANTIN M (2014) A study of terms used in scientific literature to refer to the extracapsular ligaments of the temporomandibular joint. Part I. ligamentum sphenomandibulare. *Int J Morphol*, 32(3): 981-986.
- GÓMEZ DE FERRARIS M, CAMPOS MUÑOZ A, CAR-DA BATALLA M, CARRANZA M, SÁNCHEZ QUEVEDO M (2004) *Histología, embriología e ingeniería tisular bucodental*. 3rd ed. Editorial Médica Panamericana, Buenos Aires, Madrid, p 454.
- GONZALEZ L, INFANTE P, GRANADOS M (2015) Deep dry needling of trigger points located in the lateral pterygoid muscle: Efficacy and safety of treatment for management of myofascial pain and temporomandibular dysfunction. *Med Oral Patol Oral Cir Bucal*, 1(2): 326-333.
- HAUDDODI J, LAISON F, ZOUAOUI A, BRAVETTI P, GAUDY JF (2005) Functional anatomy of the human lateral pterygoid muscle. *Surg Radiol Anat*, 27(4): 271-286.
- HUTTON B, CATALÁ-LÓPEZ F, MOHER D (2016) La extensión de la declaración PRISMA para revisiones sistemáticas que incorporan metaanálisis en red: PRISMA-NMA. *Med Clin (Barc)*, 147(6): 262-266.
- IMANIMOGHADDAM M, MADANI AS, HASHEMI EM (2013) The evaluation of lateral pterygoid muscle pathologic changes and insertion patterns in temporomandibular joints with or without disc displacement using magnetic resonance imaging. *Int J Oral Maxillofac Surg*, 42(9): 1116-1120.
- IWASAKI L, LIU H, GONZALEZ Y (2016) Modeling of muscle forces in humans with and without temporomandibular joint disorders. *Orthod Craniofac Res*, 18: 170-179.
- KAWAKAMI S, KODAMA N, MAEDA N, SAKAMOTO S, OKI K, YANAGI Y, ASAUMI J, MAEDA T, MINAGI S (2003) Mechanomyographic activity in the human lateral pterygoid muscle during mandibular movement. *J Neurosci Meth*, 15(1): 157-162.
- LA TOUCHE R, PARIS-ALEMANY A, HIDALGO-PÉREZ A, LÓPEZ-DE-URALDE-VILLANUEVA I, ANGULO-DIAZ-PARREÑO S, MUÑOZ-GARCÍA D (2018) Evidence for central sensitization in patients with temporomandibular disorders: a systematic review and meta-analysis of observational studies. *Pain Pract*, 18(3): 388-409.
- LATARJET M, RUIZ LIARD A (2005) *Anatomía Humana*. Tomo 2. 4th ed. Editorial Médica Panamericana, Buenos Aires, pp 1240-1251.
- LITKO M, SZKUTNIK J, BERGER M (2016) Correlation between the lateral pterygoid muscle attachment type and temporomandibular joint disc position in magnetic resonance imaging. *Dent Max Fac Radiol*, 45: 22-29.
- LORDUY KM, LIEGEY-DOUGALL A, HAGGARD R, SANDERS CN, GATCHEL RJ (2013) The prevalence of comorbid symptoms of central sensitization syndrome among three different groups of temporomandibular disorder patients. *Pain Pract*, 13: 604-613.
- MANISH K, WHITTLE T, PECK C (2008) Regional properties of the superior head of human lateral pterygoid muscle. *Eur J Oral Sci*, 116: 518-524.
- MATSUNAGA K, USUI A, YAMAGUCHI K, AKITA K (2009) An anatomical study of the muscles that attach to the articular disc of the temporomandibular joint. *Clin Anat*, 22(8): 932-940.
- MAZZA D, MARINI M, IMPARA L (2009) Anatomic examination of the upper head of the lateral pterygoid



- muscle using magnetic resonance imaging and clinical data. *J Craniofac Surg*, 20: 1508-1511.
- MELKE GSF, COSTA ALF, LOPES SLPC, FUZIY A, FERREIRA-SANTOS RI (2016) Three-dimensional lateral pterygoid muscle volume: MRI analyses with insertion patterns correlation. *Ann Anat*, 208: 9-18.
- MOORE K, DALLEY A, AGUR A, GUTIÉRREZ A (2013) *Anatomía con orientación clínica*. 7th ed. Wolters Kluwer Health Lippincott Williams & Wilkins, Barcelona.
- NGAMSOM S, NAKAMURA S, SAKAMOTO J (2017) The intravoxel incoherent motion MRI of lateral pterygoid muscle: a quantitative analysis in patients with temporomandibular joint disorders. *Dent Radiol*, 46: 1-8.
- OMAMI G, LURIE A (2012) Magnetic resonance imaging evaluation of discal attachment of superior head of lateral pterygoid muscle in individuals with symptomatic temporomandibular joint. *Oral Surg Oral Med Oral Pathol Oral Radiol*, 114(5): 650-657.
- OSAWA M, GROSSMAN E (2010) Anatomofisiologia do músculo pterigóideo lateral. *Rev Dor São Paulo*, 11(3): 249-253.
- PARK JT, LEE JG, WON SY, LEE SH, CHA JY, KIM HJ (2013) Realization of masticatory movement by 3-dimensional simulation of the temporomandibular joint and the masticatory muscles. *J Craniofac Surg*, 24(4): 347-351.
- PEREIRA S, FERREIRA A, GAMBOA T (2015) Lateral pterygoid muscle volume and migraine in patients with temporomandibular disorders. *Imag Sci Dent*, 45: 1-5.
- SAUNDERS S, RAINEY D (2007) *Biological anthropology of the human skeleton, nonmetric trait variation in the skeleton: abnormalities, anomalies, and atavisms*. 2nd ed. John Wiley & Sons, Inc. pp 533-559.
- SCHIFFMAN E, OHRBACH R, TRUELOVE E, LOOK J, ANDERSON G, GOULET JP, LIST T, SVENSSON P, GONZALEZ Y, LOBBEZOO F, MICHELOTTI A, BROOKS SL, CEUSTERS W, DRANGSHOLT M, ETLIN D, GAUL C, GOLDBERG LJ, HAYTHORNTHWAITTE JA, HOLLENDER L, JENSEN R, JOHN MT, DE LAAT A, DE LEEUW R, MAIXNER W, VAN DER MEULEN M, MURRAY GM, NIXDORF DR, PALLA S, PETERSSON A, PIONCHON P, SMITH B, VISSCHER CM, ZAKRZEWSKA J, DWORKIN SF (2014) Diagnostic Criteria for Temporomandibular Disorders (DC/TMD) for Clinical and Research Applications: recommendations of the International RDC/TMD Consortium Network\* and Orofacial Pain Special Interest Group. *J Oral Facial Pain Headache*, 28(1): 6-27.
- STANISZEWSKI K, LYGRE H, BIFULCO E, KVINNSLAND S, WILLASSEN L, HELGELAND E, BERGE T, ROSÉN A (2018) Temporomandibular disorders related to stress and HPA-axis regulation. *Pain Res Manag*, 70: 207-251.
- USUI A, KEIICHI A, KUMIKO Y (2008) An anatomic study of the divisions of the lateral pterygoid muscle based on the findings of the origins and insertions. *Surg Radiol Anat*, 30: 327-333.
- YOTSUYA M, SATO T, KAWAMURA S, FURUYA E, SAITO F, HISANAGA R, ONODERA K (2009) Electromyographic response in inferior head of human lateral pterygoid muscle to anteroposterior postural change during opening and closing of mouth. *Bull Tokyo Dent Coll*, 50(4): 191-198.